THE SKELETAL SYSTEM

the skeletal system consist of

- Bone.
- Cartilage
- Joint

Function of the skeletal system

1. **Support.** The skeleton forms a rigid framework to which the softer tissues and organs of the body are attached
2. **Protection.** The skull and vertebral column enclose the brain and spinal cord; the rib cage protects the heart, lungs, great vessels, liver, and spleen; and the pelvic girdle supports and protects the pelvic viscera.
3. **Body movement.**
4. **Hemopoiesis.** The process of blood cell formation is called hemopoiesis .It takes place in tissue called red bone marrow It is estimated that an average of 2.5 million red blood cells are produced every second by the red bone marrow .
5. **Fat storage.** Lipid is stored in the adipose tissue within the medullary cavity of bones. The adipose tissue and its lipid content are known as yellow bone marrow.
6. **Mineral storage.** Like calcium and phosphorus.

Types Of Bones

There are 5 types of bones in the human body. These are

- long bones,
- short bones,
- flat bones,
- irregular bones
- sesmoid bones.

Microscopic structure of the bone

At the microscopic level, spongy bone has more spaces within it than compact bone does. These spaces are filled with red marrow. Compact bone looks solid; however, the following structures can be observed with a microscope:

1.Osteons, are elongated cylinders that run up and down the long axis of the bone. Each osteon has a

- central canal that contains blood vessels and nerves.
- Lamella,Lamella are layers of bone surrounding the central canals of osteons.the lamella consist of solid bone matrix.within lamella the osteocytes hold in holes called

lacunae. The lacunae connected by tiny canals connect lacunae to each other these canals called Canaliculi.

- **Note**: Bone matrix, the matrix is the substance between bone cells. Bone cells are called osteocytes. The components of the matrix are inorganic salts, collagen fibers, and proteins. The primary salt of the matrix is calcium phosphate.

.

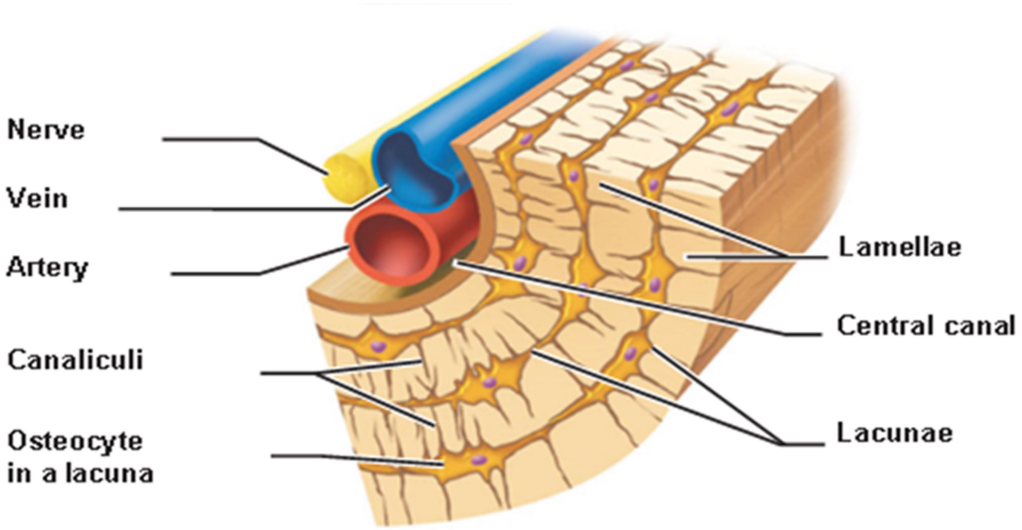

The axial and appendicular components of the skeletal system

For convenience of study, the skeleton is divided into *axial* and *appendicular portions* The axial and appendicular components of the skeletal system of an adult human consist of 206 individual bones arranged to form a strong, flexible body framework.*,*

I. The axial skeleton consists of the bones that form the axis of the body and support and protect the organs of the head, neck, and trunk. The components of the axial skeleton are as follows:

1.**Skull ,** it consist of cranial bones and facial bones.

2. **Auditory ossicles.** Three auditory ossicles are present in the middle-ear chamber .

3. **Hyoid bone.** The hyoid bone is located above the larynx and below the mandible It supports the tongue and assists in swallowing.

4. **Vertebral column.** The vertebral column consists of 26 individual bones

5. **Rib cage.** The rib cage forms the bony and cartilaginous framework of the thorax.

II.The appendicular skeleton is composed of the bones of the upper and lower extremities and the bony girdles that anchor the appendages to the axial skeleton:

1. **Pectoral girdle.**
2. **Upper extremities.**
3. **Pelvic girdle.**
4. **Lower extremities.**

SKULL

The human skull, consisting of 8 cranial and 14 facial bones.

Cranial Bones The cranial bones enclose and protect the brain and associated sensory organs. They consist of one

1. Frontal Bone The frontal bone forms the anterior roof of the cranium,the forehead, the roof of the nasal cavity,and the superior arches of the *orbits,* which contain the eyeballs

2. Parietal Bone, The two parietal bones form the upper sides and roof of the cranium. The coronal suture separates the frontal bone from the parietal bones, and the sagittal suture along the superior midline separates the right and left parietals from each other.

3. temporal bones, The two temporal bones form the lower sides of the cranium Structurally, each temporal bone has four parts.

* Squamous part, is a flattened plate of bone at the sides of the skull. Projecting forward is a zygomatic process.

* Tympanic part,it include the external acoustic meatus *and a* thin, pointed styloid process

* Mastoid part. The stylomastoid foramen, located between the mastoid and styloid processes provides the passage for part of the facial nerve.

* Petrous part, the petrous part can be seen in the floor of the cranium. The structures of the middle ear and inner ear are housed in it. It also contain,the carotid canal that allows blood into the brain via the internal carotid artery, and the jugular foramen lets blood drain from the brain via the internal jugular vein. Three cranial nerves also pass through the jugular foramen.

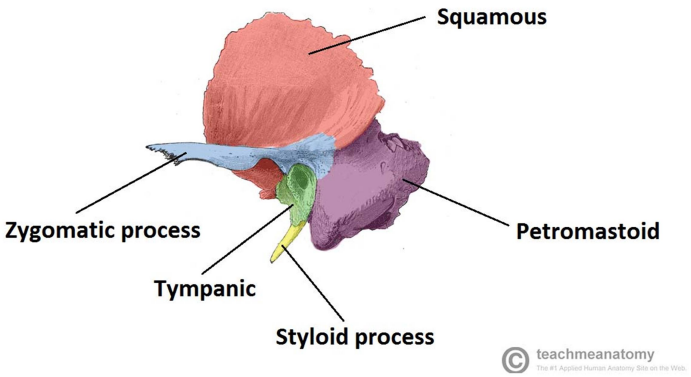

temporal bone

4.Occipital Bone

The occipital bone forms the posterior and most of the base of the skull. .It contain The foramen magnum through which the spinal cord passes to attach to the brain stem. On each side of the foramen magnum are the occipital condyles ,which articulate with the first vertebra

5.Sphenoid Bone

The sphenoid bone forms part of the anterior base of the cranium The body contains the sphenoidal sinuses and a prominent saddle like depression, the sella turcica . Commonly called "Turk's saddle," the sella turcica houses the pituitary gland. A pair of pterygoid processes project inferiorly and help form the lateral walls of the nasal cavity.

6.Ethmoid Bone

The ethmoid bone is located in the anterior portion of the floor of the cranium between the orbits, where it forms the roof of the nasal cavity.

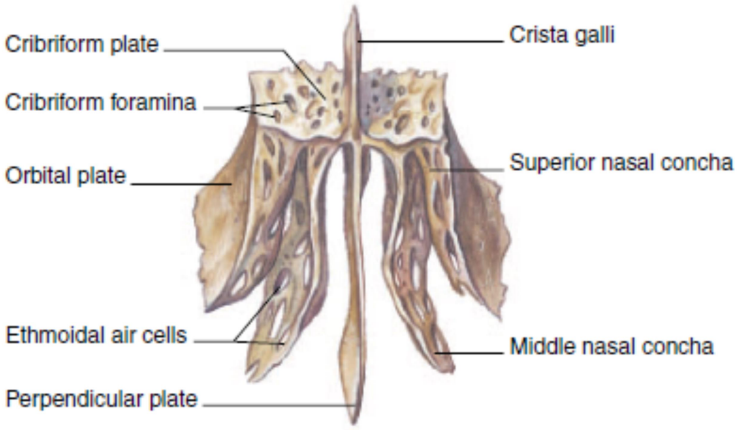

Ethmoid Bone

FACIAL BONE

1.Maxilla: The two maxillae unite at the midline to form the upper jaw, which supports the upper teeth. The **palatine process,** a horizontal plate of the maxilla, forms the greater portion of the **hard palate** or roof of the mouth. The **incisive foramen** .

2.Zygomatic Bone

The two zygomatic bones form the lateral contours of the face. A posteriorly extending *temporal process* of this bone unites with the *zygomatic process* of the temporal bone to form the **zygomatic arch** . The zygomatic bone also forms the lateral margin of the orbit.

3.Lacrimal Bone

The thin lacrimal bones form the anterior part of the medial wall of each orbit

4.Nasal Bone

The small, rectangular nasal bones join at the midlineto form the bridge of the nose. The nasal bones support the flexible cartilaginous plates, which are a part of the framework of the nose. .

5.Inferior Nasal Concha

The two inferior nasal conchae are fragile, scroll-like bones that project horizontally and medially from the lateral walls of the nasal cavity .

6.Vomer

The vomer (vo'mer) is a thin, flattened bone that forms the lower part of the nasal septum .Along with the perpendicular plate of the ethmoid bone.

7.Mandible

The mandible is the largest, strongest bone in the face. It is attached to the skull by paired temporomandibular joints, and is the only movable bone of the skull. The mandible had **body** and two **rami** . At the superior margin of each ramus is a knoblike **condylar process,** which articulates with the mandibular fossa of the temporal bone, and a pointed **coronoid process** for the attachment of the temporalis muscle.

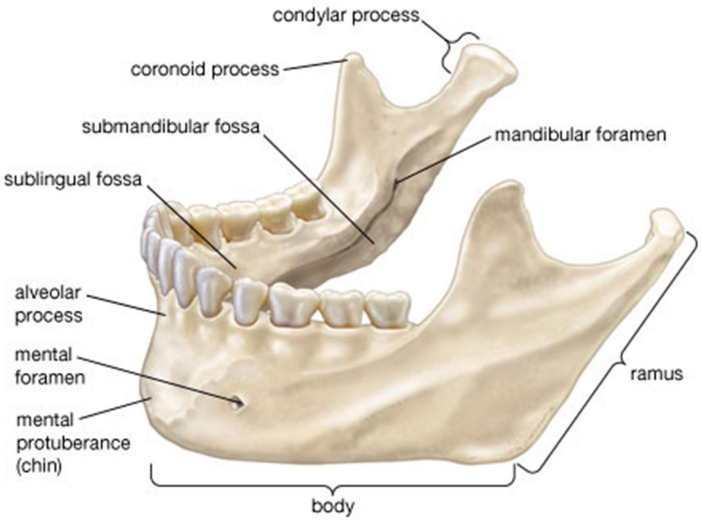

Figure: Mandible

Hyoid Bone

The single **hyoid bone** is a unique part of the skeleton in that it does not attach directly to any other bone. It is located in the neck region, below the mandible,

Auditory Ossicles

Three small paired bones, called **auditory ossicles,** are located within the middle-ear cavities in the petrous part of the temporal bones (fig. 6.31). From outer to inner, these bones are the **malleus** ("hammer"), **incus** ("anvil"), and **stapes** ("stirrup"). .

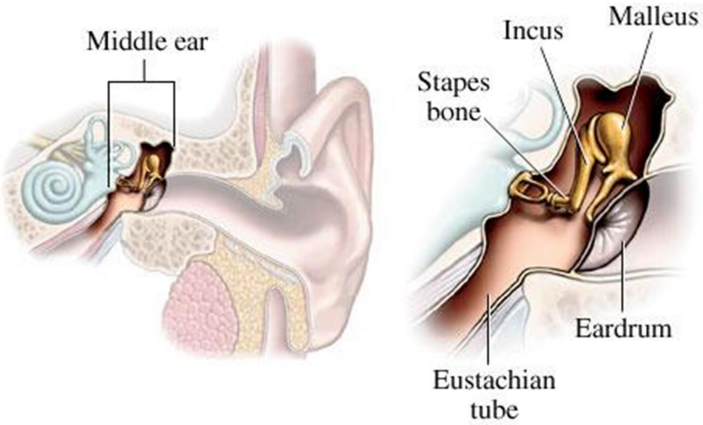

Auditory Ossicles

The vertebral column

The vertebral column is typically composed of 33 individual vertebrae.. There are 7 cervical, 12 thoracic, 5 lumbar, 3 to 5 fused sacral, and 4 or 5 fused coccygeal vertebrae. Vertebrae are separated by fibrocartilaginous intervertebral discs and are secured to each other by interlocking processes and binding ligaments. This structural arrangement permits only limited movement between adjacent vertebrae but extensive movement for the vertebral column as a whole. A typical vertebra consists of an anterior drumshaped body, which is in contact with intervertebral discs above and below . The vertebral arch is attached to.the posterior surface of the body and is composed of two supporting pedicles and two arched laminae . Seven processes arise from the vertebral arch of a typical vertebrae: the spinous process, two transverse processes, two superior articular processes, and two inferior articular processes.

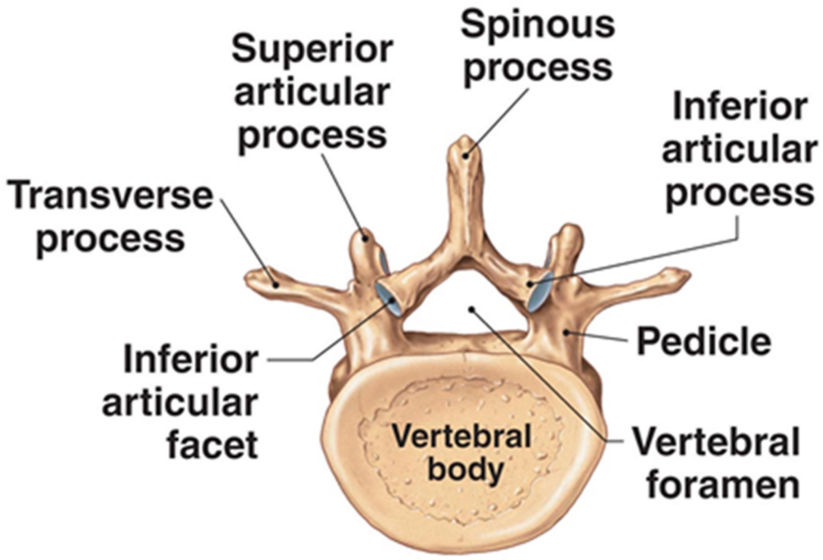

typical vertebra

The space formed by the vertebral arch and body is the vertebral foramen, through which the spinal cord passes. Between the pedicles of adjacent vertebrae are the intervertebral foramina, through which spinal nerves emerge as they branch off the spinal cord. The transverse processes of cervical spine contain a foramen (**foramen transversarium**). The vertebral arteries and veins pass through this opening as they contribute to the blood flow associated with the brain.

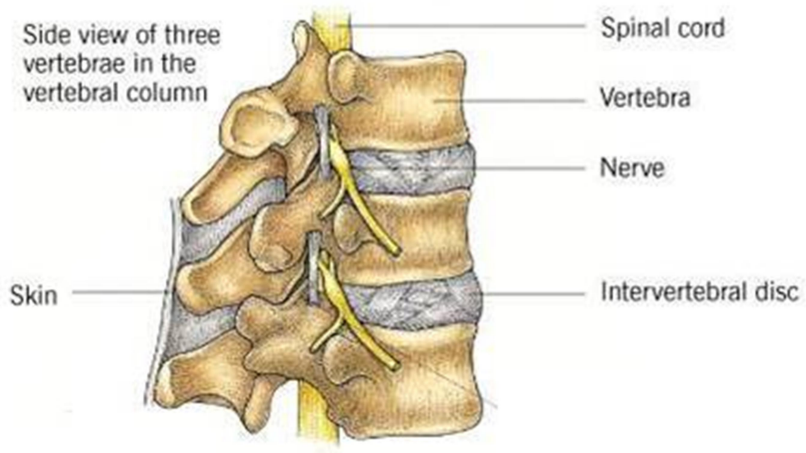

Figure: a lateral view of vertebral articulation

Sacrum

The wedge-shaped sacrum provides a strong foundation for the pelvic girdle. It consists of four or five sacral vertebrae that become fused after age 26. The sacrum has an extensive auricular surface on each lateral side for the formation of a slightly movable sacroiliac joint with the ilium. A paired superior articular processes, which articulate with the fifth lumbar vertebra, arise from the roughened sacral tuberosity along the posterior surface. The smooth anterior surface of the sacrum forms the posterior surface of the pelvic cavity.

Coccyx

The triangular coccyx ("tailbone") is composed of three to five fused coccygeal vertebrae.

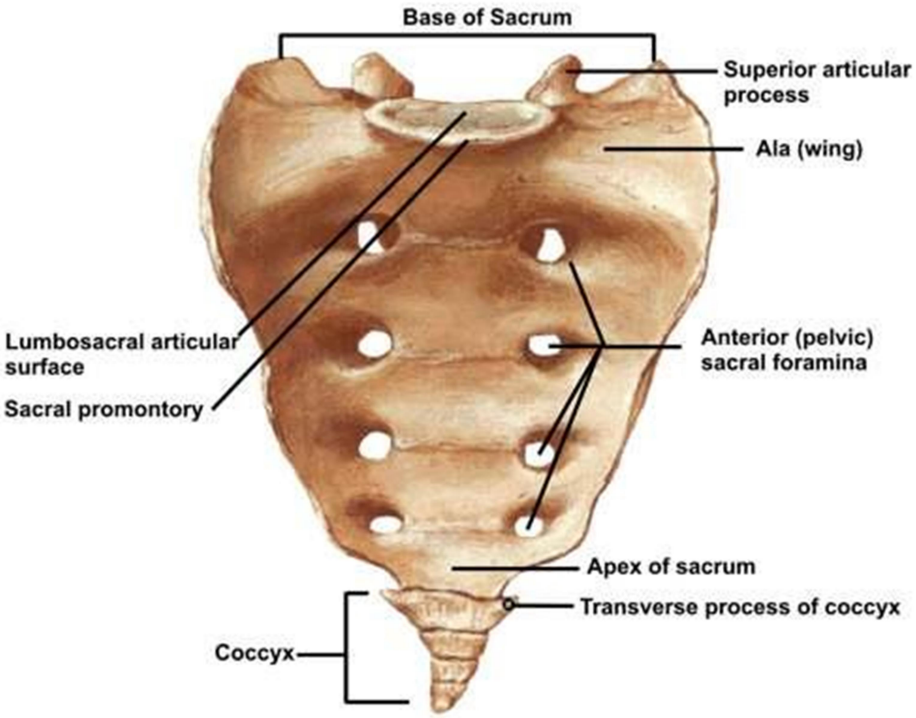

Figure: the sacrum and Coccyx

Thoracic cage

The cone-shaped, flexible rib cage consists of the thoracic vertebrae, 12 paired ribs, costal cartilages, and the sternum. The main function of thoracic cage are:

* The thorax houses and protects the heart, lungs, and great vessels. Because of the domed shape of the diaphragm, the thoracic wall also offers protection to some important abdominal viscera like liver lies under the right dome of the diaphragm, part of stomach , spleen and superior poles of the kidneys .
* is directly involved in the mechanics of breathing.

The thoracic cavity is subdivided into three major compartments:

1. a left and a right pleural cavity, each surrounding a lung.
2. The mediastinum is a thick, flexible soft tissue partition oriented longitudinally in a median sagittal position .It contains the heart, esophagus, trachea, major nerves, and major systemic blood vessels.

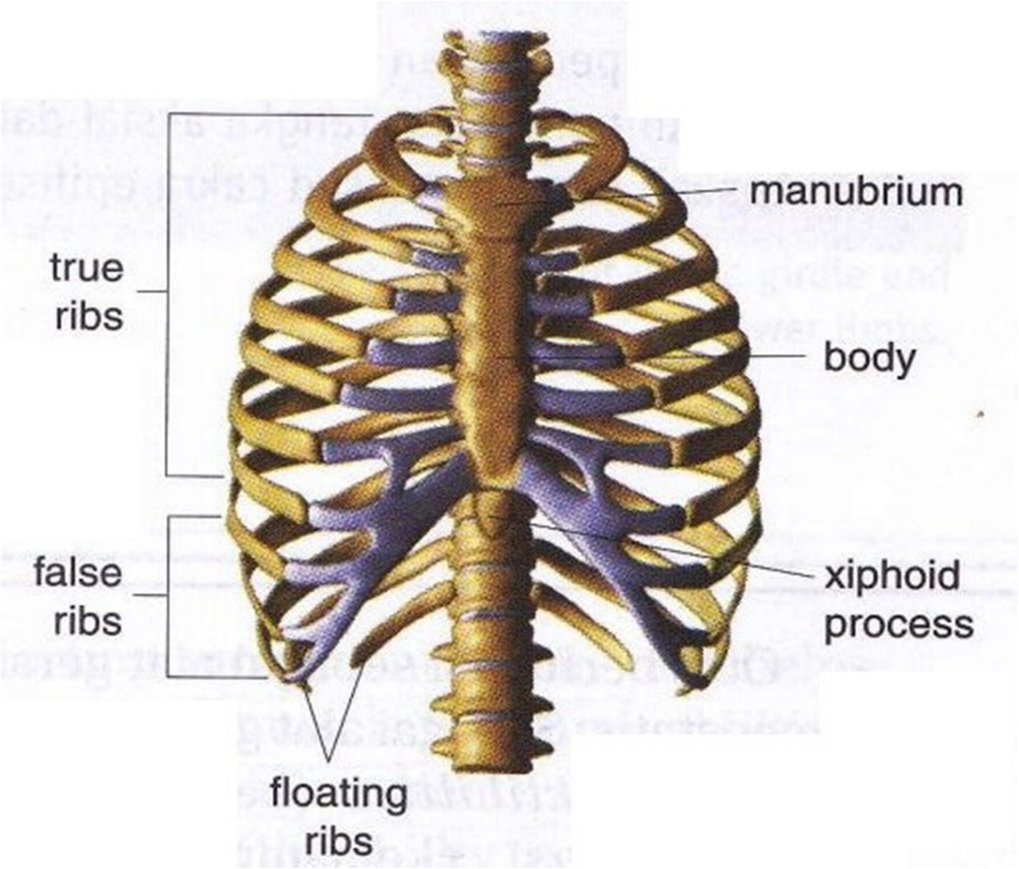

Sternum

The sternum is an elongated, flattened bony plate consisting of three separate bones:

1.the upper manubrium,

2.the central body

3.the xiphoid process,which is often cartilaginous.

On the lateral sides of the sternum are costal notches where the costal cartilages attach. A jugular notch is formed at the superior end of the manubrium, and a clavicular notch for articulation with the clavicle is present on both sides of the sternal notch. The sternal angle (angle of Louis) may be palpated as an elevation between the manubrium and body of the sternum at the level of the second rib.

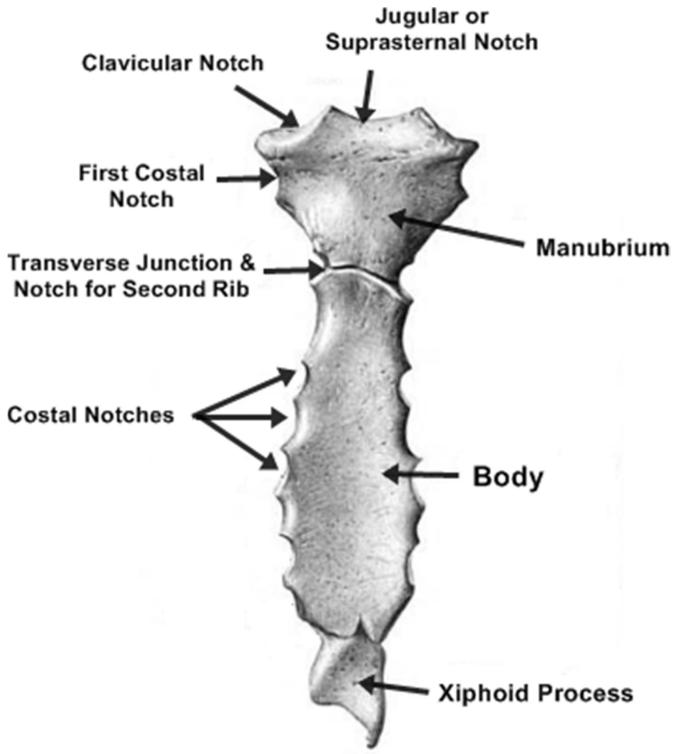

Ribs

There are 12 pairs of ribs in the thoracic cage., each rib attached posteriorly to a thoracic vertebra. Anteriorly, the first seven pairs are anchored to the sternum by individual *costal cartilages;* these ribs are called true ribs. The remaining five pairs (ribs 8, 9, 10, 11, and 12) are termed false ribs. Because the last two pairs of false ribs do not attach to the sternum at all, they are referred to as floating ribs. Each rib has a head and a tubercle for articulation with a vertebra. The head followed by a neck, angle, and body . Spaces between the ribs are called intercostal spaces and are occupied by the intercostal muscles.

Wall of the chest

The thorax wall contain two main layers

1.superficial compartment containing skin, superficial fascia, (and breasts anteriorly).

2.a deep compartment containing

- The bone frame and include ribs, sternum,vertebrae.
- The muscular layer and include intercostals muscles, in addition to the intercostals muscles the anterior chest wall contain the pectoralis major and minor. While the posterior wall contain the trapizius, latissmus dorsi and serratus muscles.
- The intercostals nerves, arteries, and veins.

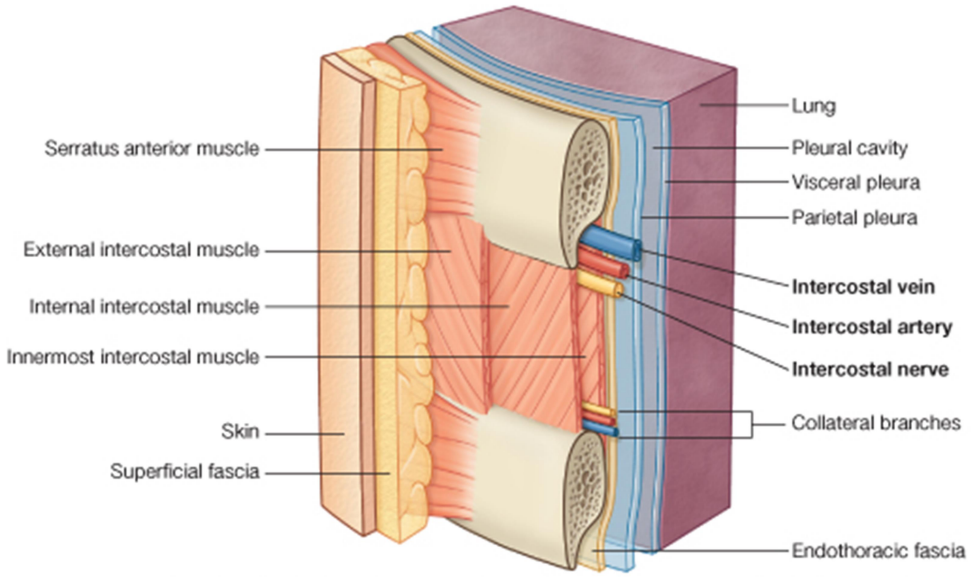

The intercostal muscles

The intercostal muscles found in intercostal space between adjacent ribs and include

1.the external intercostals muscles,move ribs superiorly during inspiration.

2.the internal intercostals muscles, move ribs inferiorly during expiration

3.the innermost intercostals muscles, act with internal intercostals muscles.

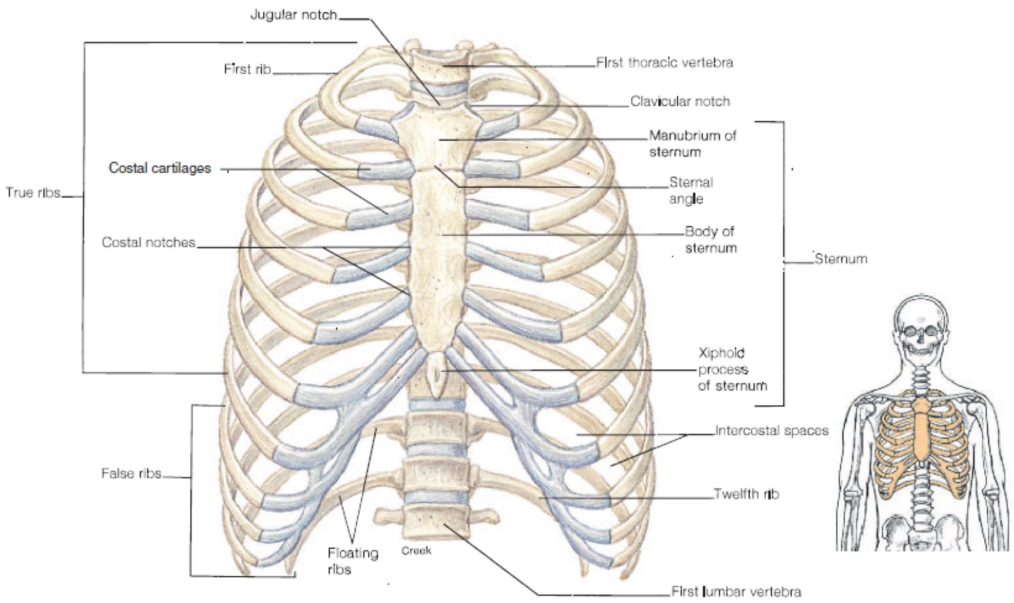

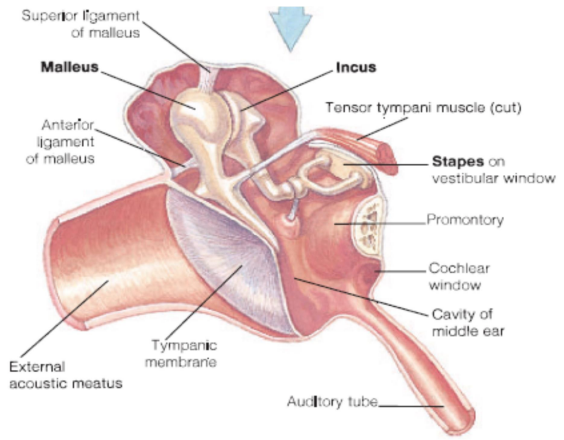

Figure: The three auditory ossicles within the middle-ear

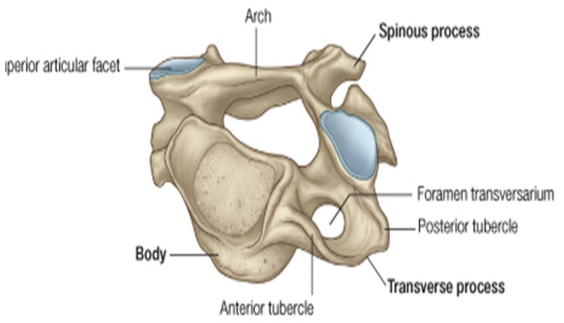

Figure:The vertebrae

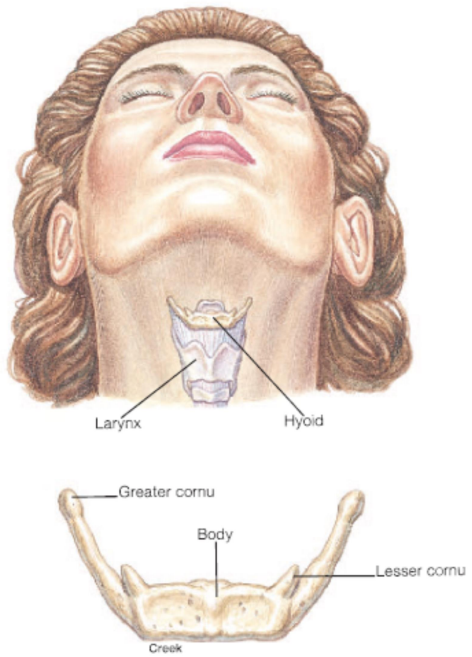

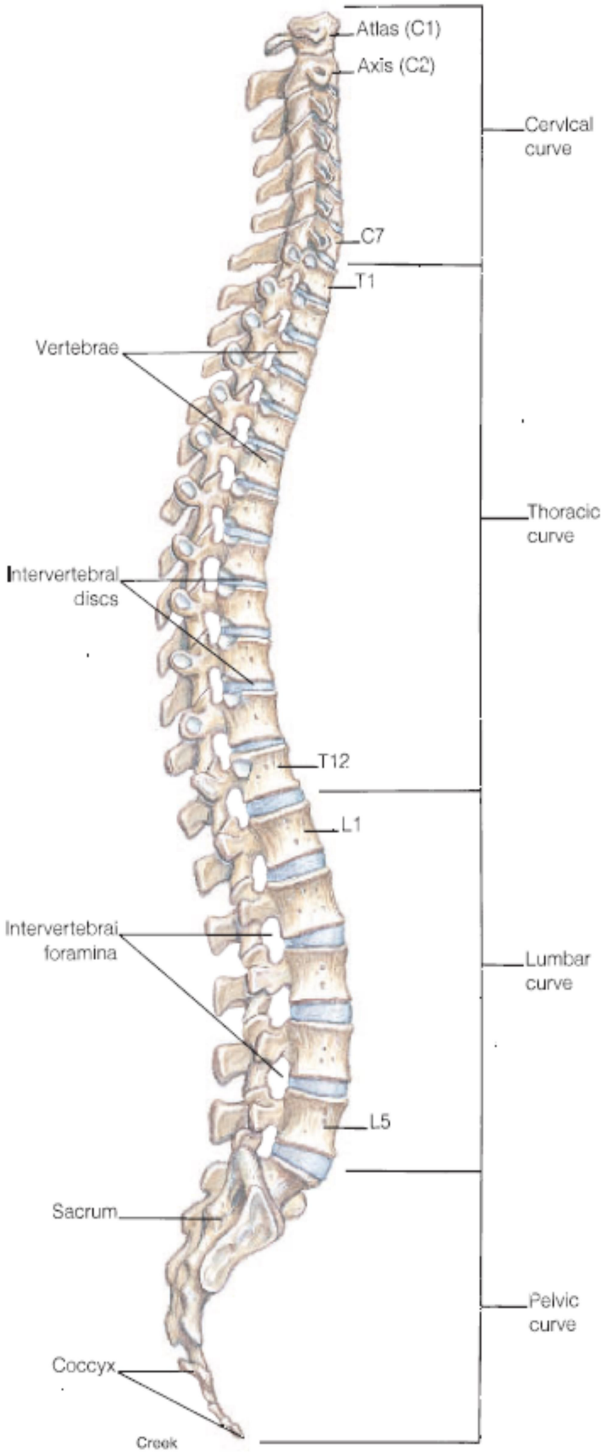

Figure : The vertebral column